


Treatment of elephants in Jaipur, India, in April 2016:

Compile by Dipl.-Biol. Tobias Dornbusch, Elephant Behaviour Consultant



Elephant 1 „Jumper“:

Foot problems: deformity of the feet and slate growth of toenails. Very heavy abrasion on the sole (*Tender Feet*), hardly wear on the heel.



Elephant 2:

Feet with less deformity and partly cracked toenails. However the elephant could not lie down, the reasons are not known:

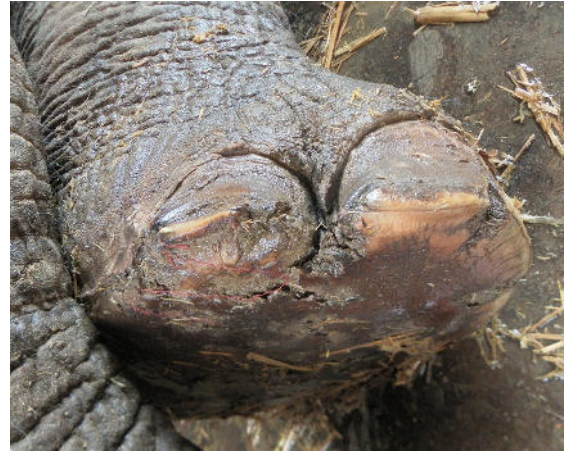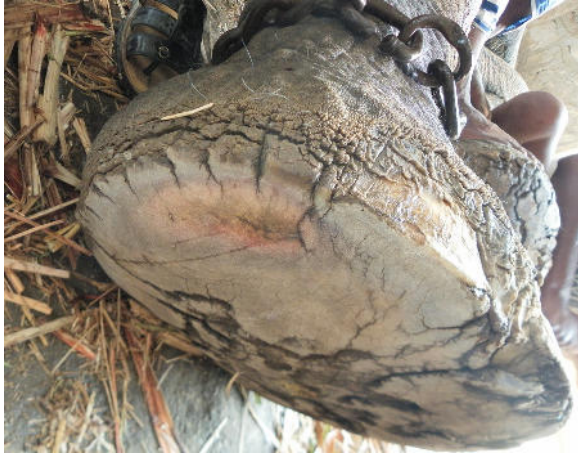No foot care possible.



Elephant 3:

Elephant with open mouth and trunk biting. -> Symptoms of pain. Heel of elephant feet with very strong abrasion. In some parts no longer sole at the heel. Therefore no pedicure.

Recommendation keep elephant on sandy soil.



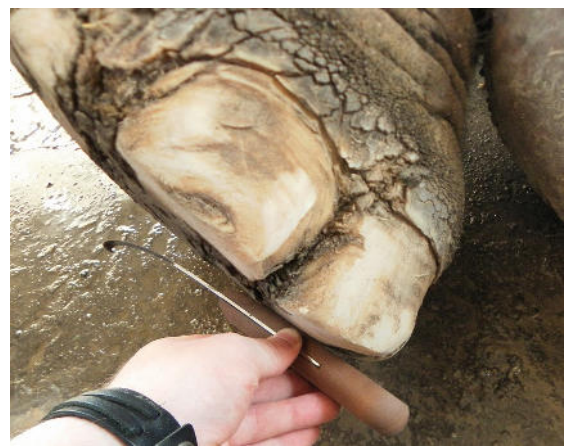
Elephant 4 „Bull-Bull“:

Uncared Feet: Low deformity of the feet; cracked toenails; Holes in the soles;
Tender Feet.



Elephant 5 „Pinky“:

Blind left eye. Inflamed Temporal gland. Foot problems: Uncared sole and toenails; Tender Feet; In addition, a wound on a toenail.



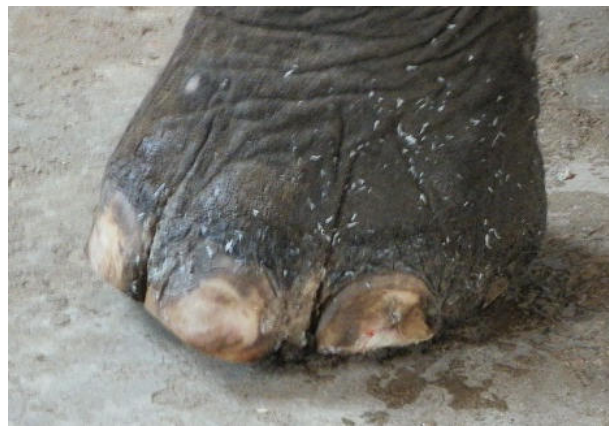Elephant 6 „Nury“:

Elephant in relatively good condition. Recognizable pedicure. Only slightly improved.



Elephant 7 „Jumper II“:

Very uncared skin. Poor foot care, especially on the hind feet too long toenails. An abscess on the torso (painted over with color).



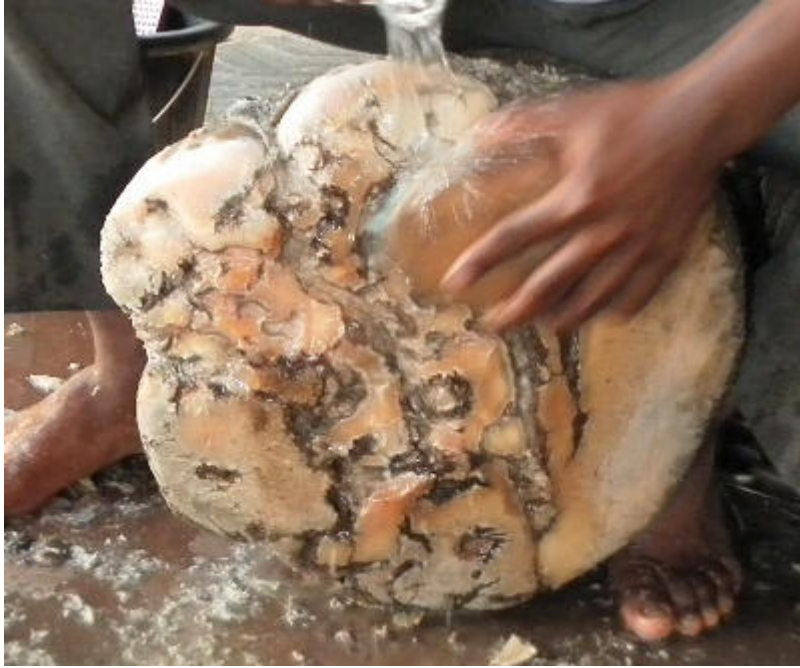Elephant 8:

Uncared toenails and soles; Numerous cracks in the toenails; Smaller holes in the sole, and large abrasion on the heel (*Tender Feet*).



Elephant 9:

Uncared toenails and soles; Numerous cracks in the nails; Traces of burn wounds (Traditional Asian Medicine).



Elephant 10:

Relatively uncared toenails and sole with small holes and the most abrasion on the heel.
The photo (above) shows the foot after foot care.